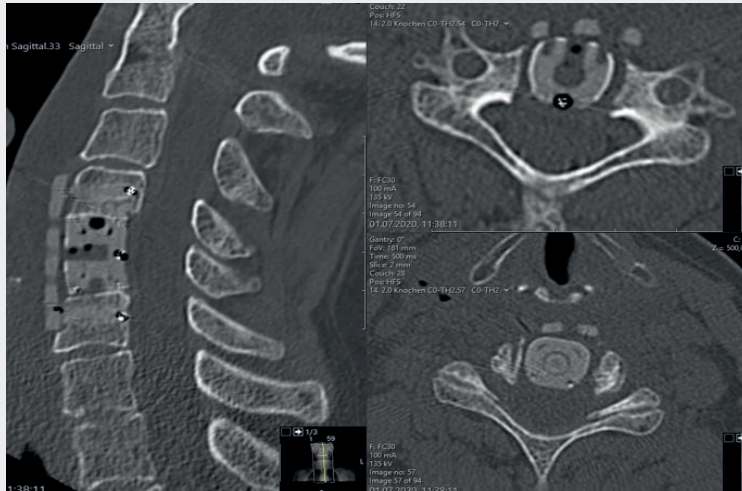


How BlackArmor® Increases Confidence in Making Decisions During Follow-Up

Post-Op CT



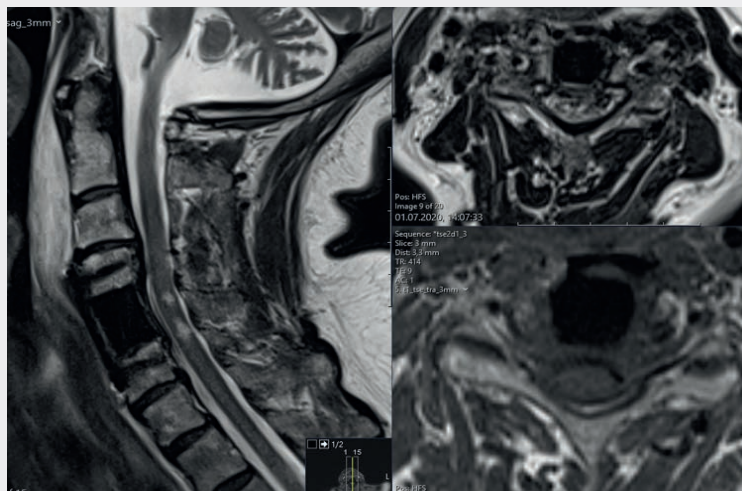
Patient

A 57-year-old female patient with myelopathy and existing C3/C4 disc degeneration was diagnosed with C4 metastasis from renal cancer.

Treatment

Vertebrectomy and anterior stabilization with the KONG®-C VBR System and the icotec Anterior Cervical Plate.

Post-Op MRI



Post-Op

Successful decompression of the spinal cord and good positioning of the implants could be assessed on low-artifact imaging without any problems.

icotec ag

Contact in the USA:

222 Pitkin Street
East Hartford CT 06108
United States
Phone: (860) 404-6999
info@icotec-medical.com
www.icotec-medical.com