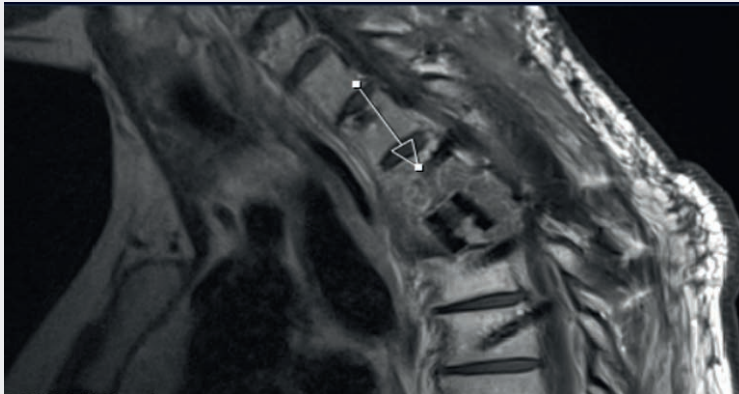


How BlackArmor® Helps to Detect Recurrence at an Early Stage

Post-Op MRI



Sagittal

Patient

41-year-old female patient with a Th3 metastasis of an esophageal adenocarcinoma.

Treatment

Laminectomy, dorsal percutaneous stabilization from Th1 to Th5 with the VADER® Pedicle System, and vertebral body replacement of Th3 with the KONG®-TL VBR System.

Follow-Up

2 months postoperatively, a small recurrence was discovered in the area of the pedicle screw tip during the regular check-up. The systemic therapeutic measures were immediately adjusted. A local tumor control could be achieved for more than 1 year.

icotec ag

Contact in the USA:

222 Pitkin Street
East Hartford CT 06108
United States
Phone: (860) 404-6999
info@icotec-medical.com
www.icotec-medical.com