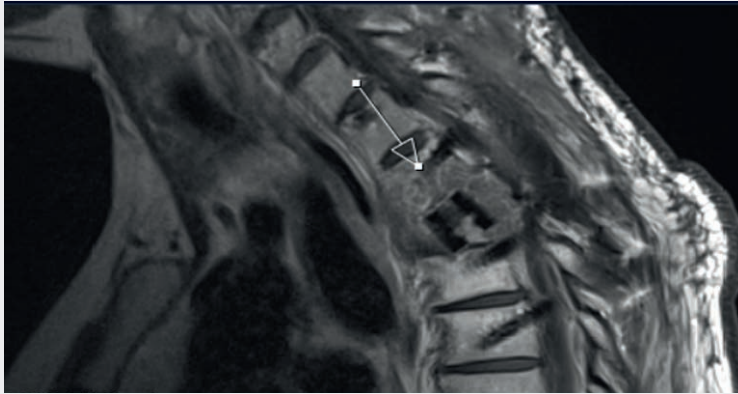


How BlackArmor® Helps to Detect Recurrence at an Early Stage

Post-Op MRI



Sagittal

Patient

41-year-old female patient with a Th3 metastasis of an esophageal adenocarcinoma.

Treatment

Laminectomy, dorsal percutaneous stabilization from Th1 to Th5 with the VADER® Pedicle System, and vertebral body replacement of Th3 with the KONG®-TL VBR System.

Follow-Up

2 months postoperatively, a small recurrence was discovered in the area of the pedicle screw tip during the regular check-up. The systemic therapeutic measures were immediately adjusted. A local tumor control could be achieved for more than 1 year.

icotec ag

Industriestrasse 12
9450 Altstätten
Switzerland
Tel +41 71 757 00 00
Fax +41 71 757 00 01
info@icotec.ch
www.icotec-medical.com