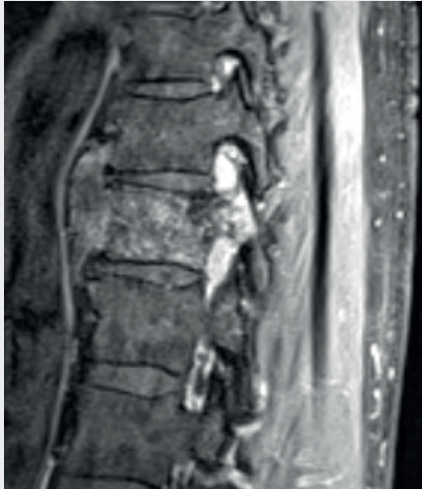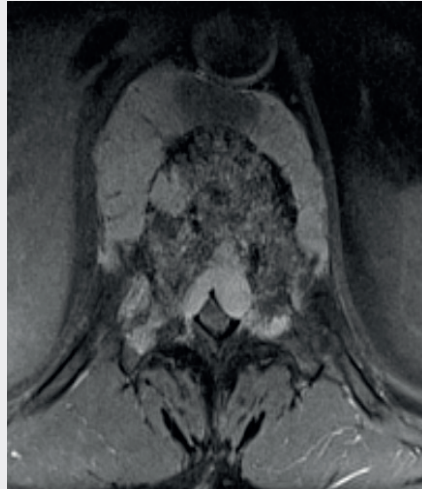


How BlackArmor® Helps Patients Access Advanced Therapies and Prevents Unnecessary Reoperations

Pre-Op MRI



Sagittal



Axial

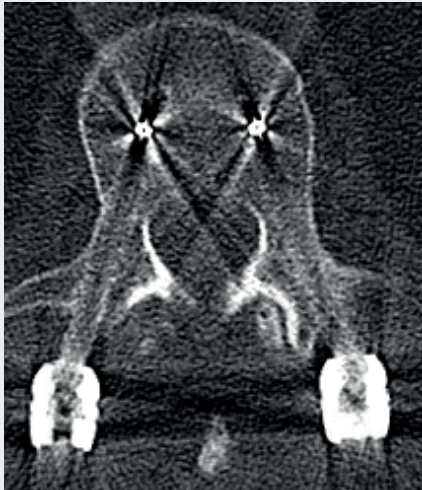Patient

60-year-old female with a suspected spinal metastasis at Th11.

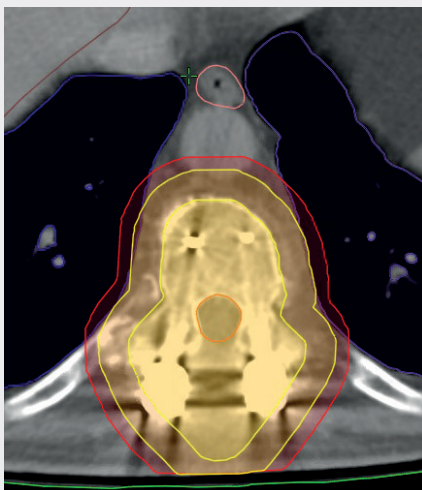
Treatment

Surgical treatment through laminectomy, debulking, biopsy, and dorsal stabilization with titanium implants.

Post-Op CT



Axial



Axial

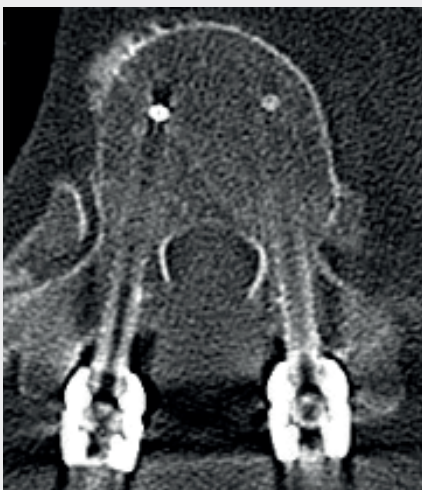Post-Op

Histological finding: Chordoma

Procedure

The resulting decision for adjuvant proton therapy called for the revision of contraindicated titanium implants and the use of BlackArmor® Carbon/PEEK implants.

17-Month Post-Op CT



Axial

Clinical Outcome

17 months postoperatively no radiological evidence of a tumor.

icotec ag

Contact in the USA:

222 Pitkin Street
East Hartford CT 06108
United States
Phone: (860) 404-6999
info@icotec-medical.com
www.icotec-medical.com