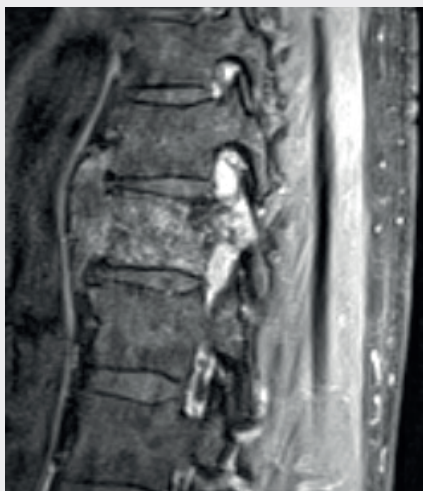

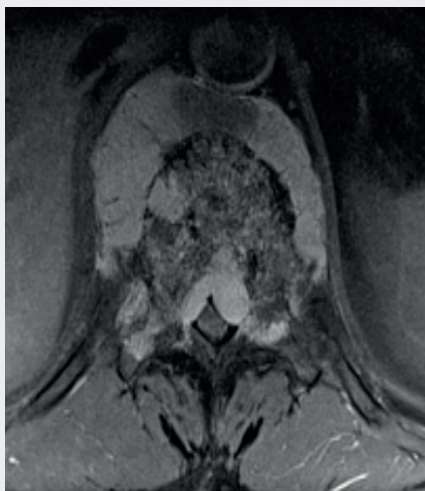
# How BlackArmor® Helps Patients Access Advanced Therapies and Prevents Unnecessary Reoperations



## Pre-Op MRI



Sagittal



Axial

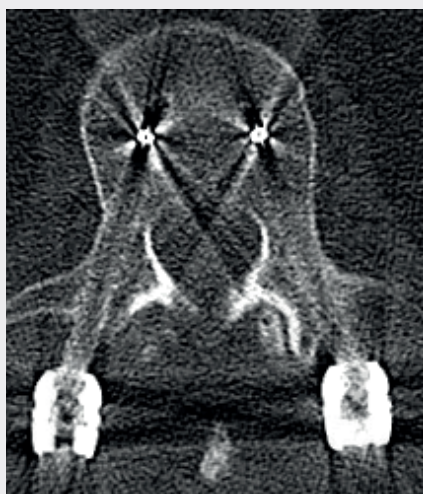### Patient

60-year-old female with a suspected spinal metastasis at Th11.

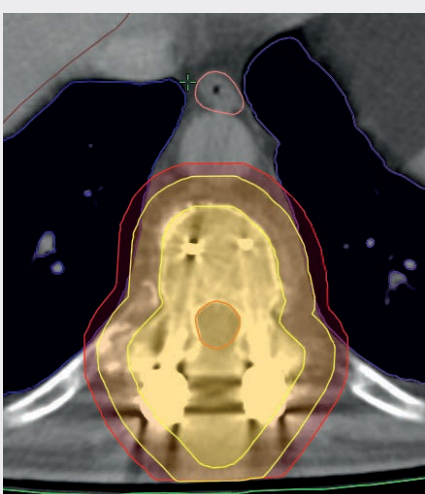
### Treatment

Surgical treatment through laminectomy, debulking, biopsy, and dorsal stabilization with titanium implants.

## Post-Op CT



Axial



Axial

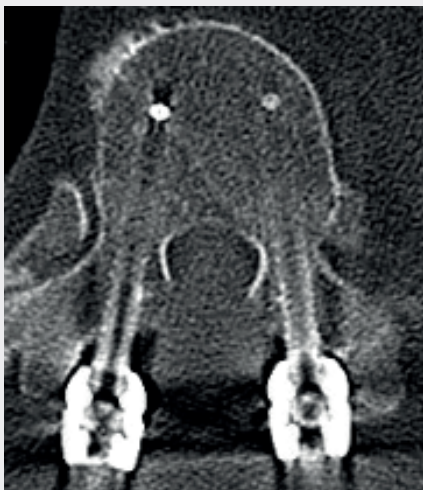### Post-Op

Histological finding: Chordoma

### Procedure

The resulting decision for adjuvant proton therapy called for the revision of contraindicated titanium implants and the use of BlackArmor® Carbon/PEEK implants.

## 17-Month Post-Op CT



Axial

### Clinical Outcome

17 months postoperatively no radiological evidence of a tumor.

#### icotec ag

Industriestrasse 12  
9450 Altstätten  
Switzerland  
Tel +41 71 757 00 00  
Fax +41 71 757 00 01  
info@icotec.ch  
www.icotec-medical.com